

Sialendoscopic Management of Salivary Stones and other Salivary Duct Pathologies

- Surgeons with Penn Otorhinolaryngology-Head and Neck Surgery are performing novel high-tech diagnostic and interventional sialendoscopy procedures to treat patients with diseases of the parotid and submandibular salivary glands.

At Penn, the primary objective for patients with sialolithiasis (stone disease) and inflammation of the salivary gland (sialadenitis) is to make a diagnosis, clear the duct and preserve the native salivary gland, if possible, and to achieve these ends using the safest, least invasive and most appropriate therapy.

In many cases, diagnosis is aided by radiography, usually after the onset of classic symptoms. Sialoliths of small to moderate size may be treated by sialendoscopy, a relatively recent innovation that is used at Penn Medicine for both diagnosis and treatment.

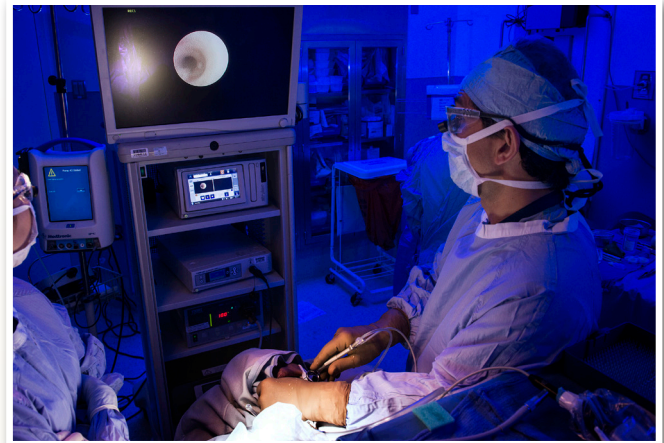About Sialendoscopy

Sialendoscopy is a minimally invasive technique that has the potential to avoid nerve injury and the facial and oral scarring associated with traditional open surgery. The sialendoscope combines a delicate, semi-rigid (1.3 mm) fiber-optic endoscope, an irrigation port and a working channel in a single instrument. The endoscope broadcasts high definition images to a monitor. (See Fig 1).

Irrigation is used to dilate the ducts, permitting exploration of the branches of the salivary duct system. The working channel is the conduit for the instruments used to remove obstructions such as salivary duct stones, including custom-designed baskets, micro-burrs and guidewires.

The approach to larger salivary stones during sialoendoscopy sometimes employs hybrid treatments such as laser fragmentation. In these cases, otorhinolaryngologists at Penn collaborate with urologists, who use similar techniques to treat kidney stones. If accessible, larger stones can thus be broken up into smaller fragments, permitting them to be eliminated by irrigation or basket retrieval.

Multiple or deeply placed stones may require a combined approach or a more limited open approach where the sialendoscope is used to transilluminate the duct.



► **Figure 1:** Christopher H. Rassekh, MD, FACS, performs a sialendoscopy at Penn Medicine for a patient with a suspected parotid duct sialolith.

In addition to sialolithiasis, the indications for sialendoscopy at Penn Medicine include ductal injuries, duct stenoses, radioactive-iodine induced sialadenitis and autoimmune sialadenitis, including Sjogren's Syndrome.

Case Study

JG, a 23-year-old male, came to Penn Medicine for suspected parotitis after experiencing repeated episodes of post-prandial facial swelling over a three month period. A CT scan at Penn found a 3mm density in JG's left parotid duct deemed highly suspicious for a salivary stone (see Fig. 2, back page). After a consultation to review his treatment options, JG opted for sialendoscopy.

At the start of the procedure, the left parotid duct papilla was dilated to permit irrigation of the duct. A 1.3 mm scope was then advanced and navigated within the duct to the obstruction, a compact sialolith, lodged at a bifurcation distal to the parotid gland.

With further irrigation to dilate the duct, a six-wire basket was placed over a guide wire and extended until it grasped the stone. At this point, the stone was gently drawn beyond the bifurcation, but floated into the opposite duct. A micro-sialendoscopic burr was then introduced, freeing the stone, which was grasped by a 3-wire basket and extracted by rotating past the muscle to the papilla. JG's recovery from surgery was unremarkable, and he was discharged the same day. At his one-year follow-up visit, there was no evidence of evolving sialoliths in the cleared duct or elsewhere.

Faculty Team

The faculty of Penn Otorhinolaryngology-Head and Neck Surgery are leaders in the field in patient care, surgical innovation and clinical and laboratory research. The Department logs more than 86,000 patient visits each year—the highest volume in the nation of any center or program performing otorhinolaryngology-head and neck surgery—and offers comprehensive and multidisciplinary programs to manage every disease or disorder affecting the organs and tissues of the nose, ears, throat, face and skull base.

Performing Sialendoscopic Procedures at Penn Medicine

Christopher H. Rassekh, MD, FACS

Associate Professor of Otorhinolaryngology-Head and Neck Surgery

Director, Penn Medicine Sialendoscopy Program

Erica R. Thaler, MD

Professor of Otorhinolaryngology-Head and Neck Surgery

Assisting with Laser Lithotripsy

Keith N. Van Arsdalen, MD

Director, Lithotripter Center

Professor of Urology in Surgery

Key Team Members

Joshua H. Atkins, MD, PhD

Assistant Professor of Anesthesiology and Critical Care

Laurie A. Loevner, MD

Professor of Radiology

Rita Glenn-West, BSN, RN, CNOR

Coordinator, Operating Room Sialendoscopy Procedures

Tashara Nicholson

Clinical Administrative Assistant

Assistant to Dr. Rassekh in Sialendoscopy Clinic

Access

Hospital of the University of Pennsylvania

5 Silverstein

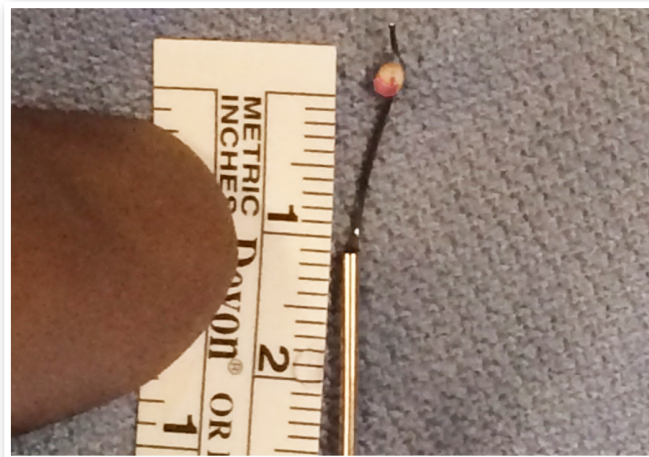3400 Spruce Street

Philadelphia, PA 19104

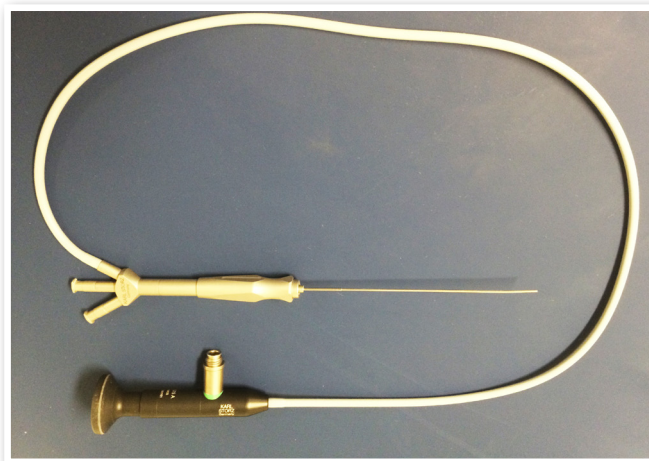


Penn Medicine

800.789.PENN PennMedicine.org



► Figure 2: A 3mm salivary stone retrieved via sialendoscopy and basket extraction.



► The STORZ sialendoscope comprises a 1.3 mm diameter high-definition endoscope (i.e., approximately the width of an 18-gauge needle) capable of entering most salivary and parotid ducts. The ports shown above represent the working (center) and irrigation (bottom) channels for the device. ©KARL STORZ GmbH & Co. KG, Tuttlingen.

Penn PhysicianLink®

Consults • Referrals • Transfers

For more information on how to make Penn PhysicianLink work for your practice and your patients, call 877.937.PENN (7366) or visit PennMedicine.org/PhysicianLink.