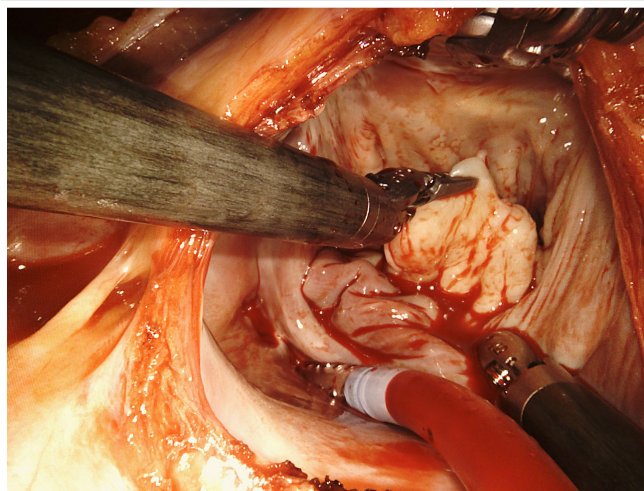


Robot-Assisted Minimally Invasive Mitral Valve Repair



► **Figure 1:** Exposure of the mitral valve during minimally-invasive robotic reparative surgery.

Cardiac surgeons with the Minimally Invasive and Robotics Program at Penn Medicine are performing robot-assisted minimally invasive mitral valve surgery (mini-MVS) as an alternative to conventional sternotomy approaches in patients with regurgitation, prolapse, annular calcification and other degenerative conditions of the mitral valve. Robot-assisted cardiac surgery has been an option for almost a decade at Penn Heart & Vascular, where surgeons also perform robotic-assisted coronary artery bypass (RACAB).

By comparison to open surgery, robotic surgery has demonstrated improved cosmesis, faster recovery times, less pain, a significant improvement in bleeding and the need for transfusion, improved early quality of life and a faster resumption of normal activities. Robotic surgery can be seen as an advance on “standard” laparoscopic MVS because it reduces and improves upon the limitations and surgical difficulty of these approaches.

Historically, the principal detractors for robotic surgery have involved the learning curve to master the technique and the lack of long-term outcomes data. Repeated studies have indicated that learning curve is an artifact of experience—and that Penn Medicine and other high volume academic medical centers have an advantage in this respect.

A recent meta-analysis suggests that robotic MVS is an effective alternative to conventional open sternotomy for both mitral valve repair and replacement, and that improvement in postoperative quality of life and faster return to work were advantages for patients having robotic surgery. [1] Moreover, in the 13 years since the FDA approved robotic cardiac surgery, a series of reports comparing robotic mitral valve surgery to conventional surgery have suggested that perioperative mortality and the incidences of stroke and reoperation for bleeding are equivalent between techniques.[2]

CASE STUDY

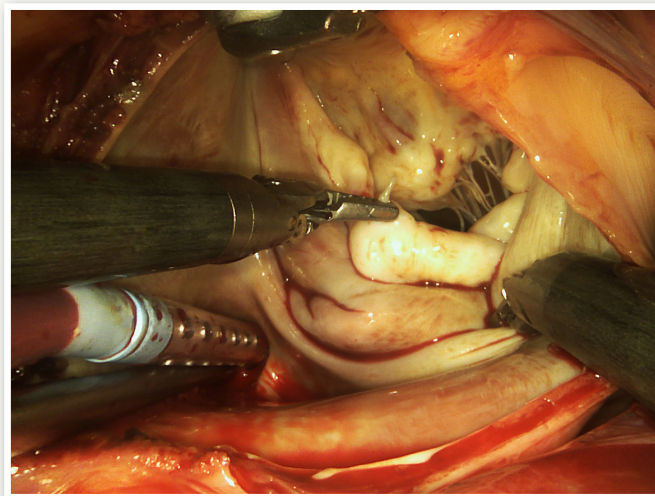
Mr. D, a 57-year-old man was referred to Penn Heart & Vascular with a 2-year history of dyspnea in the absence of exertion and postural hypotension. Mr. D's medical history also included an ablation for ventricular tachycardia and progressive hypertension, for which he took an angiotensin II receptor antagonist 100 mg and diltiazem 180 daily. There was no evidence of peripheral edema or palpitations. He did not smoke and his business did not involve an environment conducive to lung disease.

On physical examination at Penn, Mr. D was noted to have the classic click and murmur of mitral valve regurgitation. Subsequently, a transesophageal echocardiogram (TEE) revealed displacement of the posterior leaflet superior to the mitral annulus, mitral valve regurgitation and left ventricular hypertrophy. After a consultation to discuss his options, and concerned about time away from his business, Mr. D opted for a robotic mitral valve repair.

At surgery, Mr. D was placed in the supine position, and following anesthesia, right groin femoral arterial and venous cannulae were established in advance of cardiopulmonary bypass (CPB). The venous cannula was then advanced into the right atrium and confirmed by TEE. A 4 cm thoracotomy incision was made at the right anterior 4th intercostal space. The right lung was deflated and, while carefully avoiding the phrenic nerve, the pericardium opened and retracted to expose the left atrium. Two 7mm ports were then inserted in the third intercostal space and a third at the fifth space for the insertion of robotic instruments and cameras.

Cardiopulmonary bypass procedures were established. Carbon dioxide insufflation of the chest cavity was then initiated to minimize air in the heart chamber. The mitral valve was exposed and repair of the valve was conducted with a triangular resection of the posterior

(Continued on back page)



► **Figure 2:** Repair of the mitral valve with assistance of the DaVinci Robot; a ruptured chord to the posterior leaflet of the mitral valve is displayed.

(Continued from front page)

leaflet of the mitral valve and placement of an annuloplasty band. The ablation procedure was performed and the heart closed. Mr. D was successfully weaned from cardiopulmonary bypass and the incisions closed.

Mr. D tolerated his surgery well, and remained in the hospital for three days. Following his discharge home, he had a rapid recovery and returned to work three weeks later.

References

1. Seco M, et al. Systematic review of robotic minimally invasive mitral valve surgery. *Ann Cardiothorac Surg* 2013;2(6):704-716.
2. Cao C, et al. A meta-analysis of robotic vs. conventional mitral valve surgery. *Ann Cardiothorac Surg* 2015;4(4):305-314.

FACULTY TEAM

With more than two decades of experience and higher volumes than many other centers in the United States, the surgeons and vascular interventionalists of the Heart Valve Disease Program at Penn Medicine have mastered the pathodynamics of heart valve injury and the complexities of mitral and aortic valve repair and replacement. Among the nation's most experienced in all forms cardiovascular surgery, including robotic surgery, Penn cardiovascular surgeons have consistently acquired or developed innovative technologies to complement their skills in the operating room. This combination of technical and clinical expertise, experience and vision drives the constant improvement that defines the minimally invasive Surgery and Robotics Program.

Performing Robotic Mitral Valve Surgery at Penn Medicine

Pavan Atluri, MD

*Director, Minimally Invasive and Robotic Cardiac Surgery Program
Assistant Professor of Surgery*

Dr. Atluri has a specific and very focused experience on the mitral valve and robotic and other minimally invasive approaches to the mitral valve. He is considered a leader in the field with significant national recognition.

W. Clark Hargrove, MD

Clinical Professor of Surgery

ACCESS

Perelman Center for Advanced Medicine

Penn Heart and Vascular Center
East Pavilion, 2nd Floor
3400 Civic Center Boulevard
Philadelphia, PA 19104

Penn Presbyterian Medical Center

Heart & Vascular Pavilion, 4th Floor
51 N. 39th Street
Philadelphia, PA 19104